

Stroke

American Stroke
AssociationSM

JOURNAL OF THE AMERICAN HEART ASSOCIATION

A Division of American
Heart Association



Neuroprotection by Hyperbaric Oxygenation After Experimental Focal Cerebral Ischemia Monitored by MRI

Wolf-Ruediger Schäbitz, Holger Schade, Sabine Heiland, Rainer Kollmar, Jürgen Bardutzky, Nils Henninger, Harald Müller, Ulrich Carl, Shinya Toyokuni, Clemens Sommer and Stefan Schwab

Stroke 2004;35:1175-1179; originally published online Apr 1, 2004;

DOI: 10.1161/01.STR.0000125868.86298.8e

Stroke is published by the American Heart Association, 7272 Greenville Avenue, Dallas, TX 75214
Copyright © 2005 American Heart Association. All rights reserved. Print ISSN: 0039-2499. Online
ISSN: 1524-4628

The online version of this article, along with updated information and services, is
located on the World Wide Web at:

<http://stroke.ahajournals.org/cgi/content/full/35/5/1175>

Subscriptions: Information about subscribing to *Stroke* is online at
<http://stroke.ahajournals.org/subscriptions/>

Permissions: Permissions & Rights Desk, Lippincott Williams & Wilkins, 351 West Camden
Street, Baltimore, MD 21202-2436. Phone 410-5280-4050. Fax: 410-528-8550. Email:
journalpermissions@lww.com

Reprints: Information about reprints can be found online at
<http://www.lww.com/static/html/reprints.html>

Neuroprotection by Hyperbaric Oxygenation After Experimental Focal Cerebral Ischemia Monitored by MRI

Wolf-Ruediger Schäbitz, MD; Holger Schade; Sabine Heiland, PhD; Rainer Kollmar, MD; Jürgen Bardutzky, MD; Nils Henninger, MD; Harald Müller, MD; Ulrich Carl, MD; Shinya Toyokuni, MD, PhD; Clemens Sommer, MD; Stefan Schwab, MD

Background—Hyperbaric oxygenation (HBO) after focal cerebral ischemia reduces infarct size and improves outcome when applied early after stroke. Here, we evaluated effects of HBO on permanent focal cerebral ischemia and applied magnetic resonance imaging (MRI) monitoring to study lesion evolution.

Methods—Rats underwent permanent middle cerebral artery occlusion (MCAO). Two hours later, animals were treated with HBO (100% O₂/2 atm; n=17) for 1 hour or treated with room air (n=17). Animals underwent serial MRI studies (DWI, PI, T2) beginning 90 minutes after MCAO. Neuroscore was assessed (5-point rating scale). Animals were euthanized and brains were 2,3,5-triphenyltetrazolium chloride (TTC)-stained for infarct volume calculation 120 hours after MCAO. Immunohistochemistry was performed with antibodies against c-FOS and 4-hydroxy-2-nonenal-modified proteins (HNE) to check for effects of oxidative stress caused by HBO treatment.

Results—HBO reduced infarct volume by 38% ($P<0.001$). As shown by MRI, neuroprotection began 5 hours after ischemia and remained effective for 5 days. The relative regional cerebral blood flow was not different between groups at 3.5 and 5 hours after occlusion. There was less neurological deficit in HBO-treated animals compared with controls ($P<0.05$). Lipid peroxidation of cerebral vessels after HBO treatment as measured by HNE staining and pattern of c-FOS induction were not significantly different between groups at 3.5 and 8 hours after ischemia.

Conclusion—As monitored by MRI HBO treatment reversed ischemic lesion size between 3 and 5 hours after ischemia and achieved a long-lasting neuroprotective effect without significant oxidative damage. (*Stroke*. 2004;35:1175-1179.)

Key Words: hyperbaric oxygenation ■ focal cerebral ischemia ■ MRI ■ lipid peroxidation ■ neuroprotection

Treatment with hyperbaric oxygen (HBO) is protective in various models of focal cerebral ischemia.¹⁻⁶ A recent controlled trial with 33 patients was negative,⁷ but only 10% of patients received HBO treatment within 3 to 6 hours after stroke. Because it is well perceived from experimental studies that HBO treatment beyond 6 hours after onset of ischemia is ineffective and could even deteriorate outcome,^{6,8} the negative result was not surprising. HBO treatment, however, could still be beneficial for a subgroup of patients who, for other reasons, cannot be treated with rt-PA, craniectomy, or hypothermia.

We therefore studied in this experiment a clinically relevant situation with onset of HBO treatment 2 hours after permanent ischemia. Magnetic resonance imaging (MRI)-measured diffusion-weighted imaging (DWI), perfusion-weighted imaging (PWI), and T2-weighted imaging were applied to monitor lesion evolution, treatment effectiveness,

and immunohistochemistry to check for markers of oxidative stress.

Materials and Methods

Experimental Groups

All experimental procedures were performed in accordance with European Communities Council Directive (86/609/EEC) and approved by the local ethics committee. Male Wistar rats (300 to 315 g; Charles River Wiga, Sulzfeld, Germany) were randomly assigned before surgery to room air treatment at atmospheric pressure (n=17) or to HBO treatment (2 atm, 100% oxygen, 60 minutes, beginning 2 hours after ischemia) (n=17) and consecutive MRI monitoring. For immunohistochemistry, HBO-treated, room air-treated, and sham-operated rats (n=5 per group at 3, 5, and 8 hours after stroke onset) were investigated.

Surgery

Rats were weighed and intraperitoneally anesthetized with ketamine (100 mg/kg) and rompun (8 mg/kg). The left femoral artery was

Received June 2, 2003; final revision received December 1, 2003; accepted January 21, 2004.

From Departments of Neurology (W.R.S., H.S., R.K., J.B., S.S.) and Neuroradiology (S.H.), University of Heidelberg, Germany; Division of Neuropathology (H.M., C.S.), University of Ulm, Germany; Department of Radiology (U.C.), Diakonie Krankenhaus, Rottenburg, Germany; Department of Pathology and Biology of Diseases (S.T.), Graduate School of Medicine, Kyoto University, Japan.

Correspondence to Dr Clemens Sommer, Division of Neuropathology, Department of Pathology, University of Ulm, Albert-Einstein-Allee 11, D-89081 Ulm, Germany. E-mail clemens.sommer@medizin.uni-ulm.de

© 2004 American Heart Association, Inc.

Stroke is available at <http://www.strokeaha.org>

DOI: 10.1161/01.STR.0000125868.86298.8e

cannulated with PE-50 polyethylene tubing for continuous monitoring of arterial blood pressure and blood sampling for analysis of arterial blood gases measured before and after treatment in the chamber. Core temperature was maintained at 37°C during surgery using a heating lamp. Occlusion of the middle cerebral artery (MCA) was induced using the suture occlusion technique.⁹ The right common carotid artery and the right external carotid artery were exposed, and a 4-0 monofilament nylon suture (Ethicon) coated with silicon (Bayer) was inserted through an arteriotomy in the common carotid artery, advanced into the internal carotid artery, and positioned 17 mm from the carotid bifurcation. After surgery, HBO treatment, and MR measurements, the catheters were removed, and the animals were allowed to recover from anesthesia.

HBO Treatment

Animals were placed in a custom-made pressure chamber of transparent acrylic plastic (inner diameter 25 cm, length 50 cm) 2 hours after ischemia. They were packed into a warming fleece (4 mm) with an isolating aluminum membrane (1 mm) to keep body temperature at 37°C. HBO-treated animals were pressurized within 10 minutes to 2 atm/100% oxygen and maintained for 60 minutes. Controls were also transferred into the chamber, but not pressurized, and they breathed room air.

MRI Protocol

Animals were examined in a 2.35 T scanner (Biospec 24/40; BRUKER Medizintechnik). An actively shielded gradient coil with 120-cm inner diameter driven by the standard 150-V/100-A gradient power supply was used. In this configuration, 180 mT/m could be reached in 180 ms. As rapid frequency (RF) coil, we used a home-built birdcage resonator with 40-mm inner diameter.

MR examination was performed at 1.5, 3.5, and 5 hours (DWI, PWI, T2) and on day 1, 2, and 5 (T2) after vessel occlusion, respectively. In each animal, we performed diffusion-weighted MRI using a spin-echo echo-planar imaging (EPI) sequence (repetition time [TR]=3 s, echo time [TE]=67.7 ms, number of averages [NA]=3, 8 different b-values from 0 to 1260 s/mm², diffusion time=50 ms, duration of diffusion gradient=5, field of view [FOV]=4.5 cm×4.5 cm, matrix=128×64, 6 slices, slice thickness [thk]=2 mm), T2-weighted MRI using a RARE sequence (TR=3 s, TE=87 ms, NA=4, FOV=4.5 cm×4.5 cm, matrix=256×256, 6 slices, thk=2 mm), and PWI using a gradient-echo EPI sequence (TR=1 s, TE=12 ms, NA=1, FOV=4.5 cm×4.5 cm, matrix=128×64, 4 slices, thk=2 mm, number of repetitions [NR]=20, time resolution [Δt]=1 s). For PW MRI, a bolus of 0.5 mmol/kg body weight Gd-DTPA (Omniscan; Schering AG) was injected before acquisition of the fifth image data set.

Image data were transferred to a SUN sparstation 10 (SUN Microsystems). From T2-weighted MRI, we (H.S.) calculated volume of infarction, and from the DWI, we calculated apparent diffusion coefficient as described in Heiland et al¹⁰ The ischemic lesions in T2-weighted imaging were defined as hyperintense areas on the image with the highest T2 weighting (TE=96 ms). A side-by-side difference of apparent diffusion coefficient value from homologous pixels (ischemic and normal hemispheres that best define the ischemic lesion volume in vivo) of 45%, highly correlating with postmortem infarct volume, was used to define abnormal ischemic pixels.¹¹ From PWI data, we calculated relative regional cerebral blood volume (rCBV) and relative mean transit time (rMTT) (region of interest [ROI] 1: anterior cerebral artery supplied cortex; ROI 2: parietal cortex; ROI 3: temporal cortex; ROI 4: basal cortex; ROI 5: caudoputamen).

Follow-up Assessment

Animals were weighed and neurologically assessed by an investigator blinded to the treatment administered on days 1 and 5 (H.S.) (rating scale: 0=no deficit, 1=failure to extend the left forepaw, 2=decreased grip strength of left forepaw, 3=circling to left by pulling the tail, 4=spontaneous circling).¹² After 5 days, animals were anesthetized again with ketamine/rompune, and decapitated,

and the brains were sectioned into 5 2-mm coronal slices, incubated for 30 minutes in 2% solution of 2,3,5-triphenyltetrazolium chloride (TTC) at 37°C, and photographed (slices 1 to 5=bregma coordinates +2.4, +0.4, -1.6, -3.6, and -5.4, respectively). Infarct volumes were calculated by an investigator blinded to the treatment administered (H.S.), and were quantified for each slice using image-processing software (NIH Image). To compensate for the effect of brain edema corrected infarct volume was calculated as left hemisphere area minus (right hemisphere area minus infarct area).¹³

Morphological Analysis and Immunohistochemistry

For morphological analysis, 3-μm-thick paraffin sections (1 section per staining) sampled at the level of the dorsal hippocampus were used. Immunohistochemistry was performed with antisera against 4-hydroxy-2-nonenal (HNE)-modified proteins, as previously described,^{14,15} and against c-FOS (1:200; Santa Cruz Biotechnology Inc), and a monoclonal mouse antibody was performed against the CD34 antigen (dilution 1:20; clone My10; Becton Dickinson Immunocytometry Systems). For antigen retrieval, sections were heated for 20 minutes in a 10-mmol/L citrate buffer at 99°C. After incubation in normal swine serum (10%) for 30 minutes followed by the primary antibody for 1 hour, immunoreactivity (IR) was visualized by the avidin biotin complex method (Vectastain; Vector Laboratory Inc) with consecutive enhanced diaminobenzidine staining. Immunohistochemical analysis was performed by investigators blinded to the treatment assignment (H.S., H.M., C.S.). Infarct boundaries were determined using H&E-stained sections and marked under the microscope. The total number of CD34 and HNE positive vessels was counted within the marked boundaries. The c-FOS IR was analyzed within cortex, thalamus, and hippocampus using a semiquantitative grading scheme (0: only a few scattered immunoreactive cells; 1: <20%, 2: >20% and <50%, 3: >50% immunoreactive cells).

Values presented are means±SD. After acquiring data, the randomization code was broken. ANOVA and post hoc Fisher protected least significant difference test or Bonferroni error protection were used for comparison of continuous variables (physiological parameter, MRI, immunohistochemistry), *t* test was used for infarct volume, and Mann-Whitney *U* test was used for nonparametric data (mortality, neuroscore). *P*<0.05 was considered statistically significant.

Results

DWI-derived ischemic lesion volumes 90 minutes after vessel occlusion (30 minutes before HBO treatment) were 176.4±32.9 mm³ for controls and 173.8±19.3 mm³ for HBO-treated animals (not significant). DWI-derived lesion volumes increased to 211.3±39.6 and 193.6±16.7 (NS) at 3.5 hours, and 211.1±39.9 mm³ and 175.5±22.1 mm³ (*P*<0.05) at 5 hours for controls and HBO-treated animals, respectively. There were no infarcts on T2-weighted images at 1.5 and 3.5 hours after occlusion. T2-weighted-derived lesion volumes were 236.8±21.4 mm³ and 192.0±22.6 mm³ (*P*<0.05) at 5 hours after occlusion, and 258.8±14.8 mm³ and 215.7±18.5 mm³ (*P*<0.05) at 24 hours for controls and HBO-treated animals, respectively. T2-weighted-derived lesion volume then increased to 289.4±22.0 mm³ and 237.1±26.6 mm³ (*P*<0.05) at 48 hours, and decreased to 236.5±30.6 mm³ and 180.1±13.9 mm³ (*P*<0.05) at day 5 for controls and HBO-treated animals, respectively (Figures 1 and 2). This corresponded to postmortem infarct volume of 265±29.6 mm³ in the control group and 178.1±38.4 mm³ in the HBO-treated group (Figure 2).

Cerebral blood flow (CBF) was calculated for each ROI at each of the 3 time points based on the rCBV and rMTT data

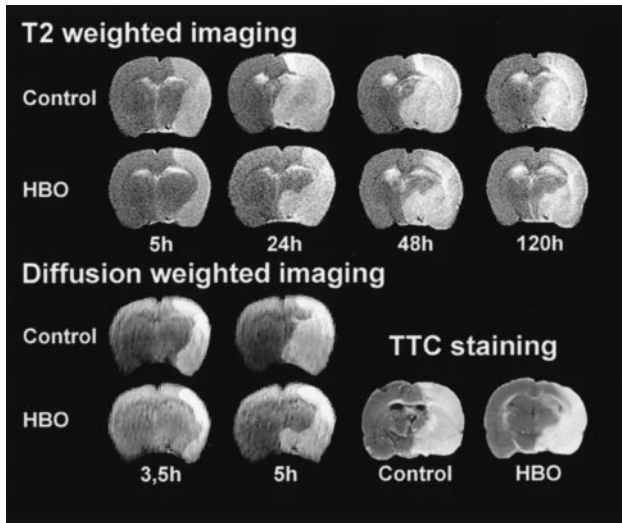


Figure 1. Ischemic lesion evolution measured by DWI and T2-weighted imaging in room-air-treated and HBO-treated animals. Postmortem TTC staining on day 5 is shown at the lower right. Note the long-lasting (5 days) neuroprotection achieved by HBO treatment, effective as early as 5 hours after vessel occlusion.

and was compared between the 2 experimental groups. The relative regional cerebral blood flow (rrCBF) was reduced 70% before reperfusion in all ROIs except for ROI 1 (ACA territory). There was no significant difference in rrCBF between controls and HBO-treated animals at 3.5 and 5 hours after occlusion (not shown).

In HBO-treated animals, there was less neurological deficit compared with controls on day 1 (2.8 ± 0.6 versus 3.6 ± 0.7 ; $P < 0.05$) and day 5 (2.8 ± 0.8 versus 3.6 ± 0.5 ; $P < 0.05$). Weight loss was not significantly different. There was no difference in mortality between the groups: 6 animals in the HBO-treated group and 5 animals in the control group died because of massive brain edema with signs of uncal herniation between 16 and 36 hours after occlusion¹⁶ and were excluded from MRI analysis. Except a significant increase in pO_2 after HBO treatment, no other differences occurred in

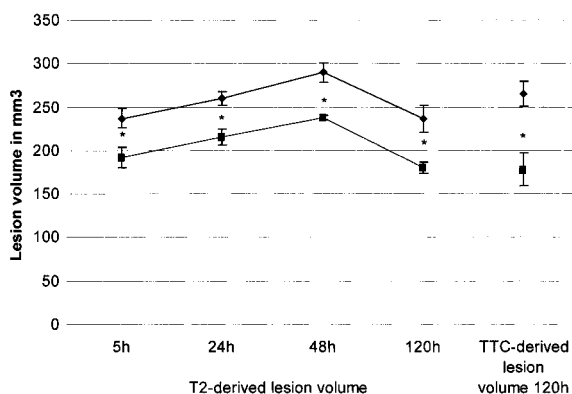


Figure 2. Serial changes in evolution of T2-derived ischemic lesion volumes in HBO-treated animals (squares) and controls (diamonds) after permanent focal cerebral ischemia. Neuroprotection began 5 hours after ischemia, remained effective throughout 5 days, and correlated to postmortem TTC-derived infarct volume. Values are mean \pm SD ($*P < 0.05$; ANOVA, Fisher test), time is given nonlinear in days (x-axis).

Physiological Data During Surgery and Before and After HBO Treatment

Baseline	Control		HBO-Treated	
	Mean Value	SD	Mean Value	SD
pH	7.4	± 0.06	7.4	± 0.05
PCO ₂ (mm Hg)	48.1	± 11.5	44.2	± 6
pO ₂ (mm Hg)	106.1	± 7.1	108	± 5.9
BE	0.3	± 0.5	0.3	± 0.7
MCAO				
pH	7.4	± 0.05	7.4	± 0.02
PCO ₂ (mm Hg)	47.9	± 4.3	44.4	± 5
pO ₂ (mm Hg)	106.7	± 5.5	107.4	± 4.9
BE	0.02	± 0.6	0.0	± 0.4
Before HBO				
pH	7.4	± 0.02	7.3	± 0.03
PCO ₂ (mm Hg)	49.5	± 2.6	48.07	± 3.1
pO ₂ (mm Hg)	103.9	± 3.6	106.7	± 5
BE	-0.1	± 0.5	-0.02	± 0.7
Temperature (°C)	37.24	± 0.19	37.19	± 0.12
After HBO				
pH	7.4	± 0.02	7.4	± 0.06
PCO ₂ (mm Hg)	46.2	± 4.1	44.2	± 5.4
pO ₂ (mm Hg)	117.9	± 6.5	152.9*	± 11.6
BE	0.1	± 0.5	-0.01	± 0.6
Temperature (°C)	37.10	± 0.09	36.94	± 0.47

Body temperature during surgery was kept at 37°C. Values are mean \pm SD. $*P < 0.05$; ANOVA, Fisher test.

physiological parameters between HBO-treated animals and controls (Table).

Lipid peroxidation as measured by HNE staining was restricted to capillary endothelial cells. As a measure, the ratio of HNE-positive vessels from all vessels within the infarcted area was calculated. HNE staining was not significantly different between treated animals and controls at 3.5 hours after ischemia (0.32 ± 0.4 versus 0.33 ± 0.08 , respectively; NS) (Figure 3) and at 8 hours after ischemia (0.21 ± 0.04 versus 0.24 ± 0.07 , respectively; NS). Sham-operated HBO-treated controls exhibited no significant HNE staining (ratio of HNE-positive vessels from all vessels at 3.5 hours 0.06 ± 0.02 and at 8 hours 0.05 ± 0.02).

Marked c-FOS induction was visible at 3.5 hours in the entire ischemic hemisphere both in control and HBO-treated rats, which already declined at 8 hours. Within the contralateral hemisphere, only a slight induction within the dentate gyrus was present. There was a tendency of stronger c-FOS IR in the hippocampus of non-HBO-treated rats at both time points investigated, but this reached no significance (not shown).

Discussion

HBO treatment in the present study (2 atm, 100% oxygen, 60 minutes, beginning 2 hours after ischemia) was based on previous experiments demonstrating effectiveness with treat-

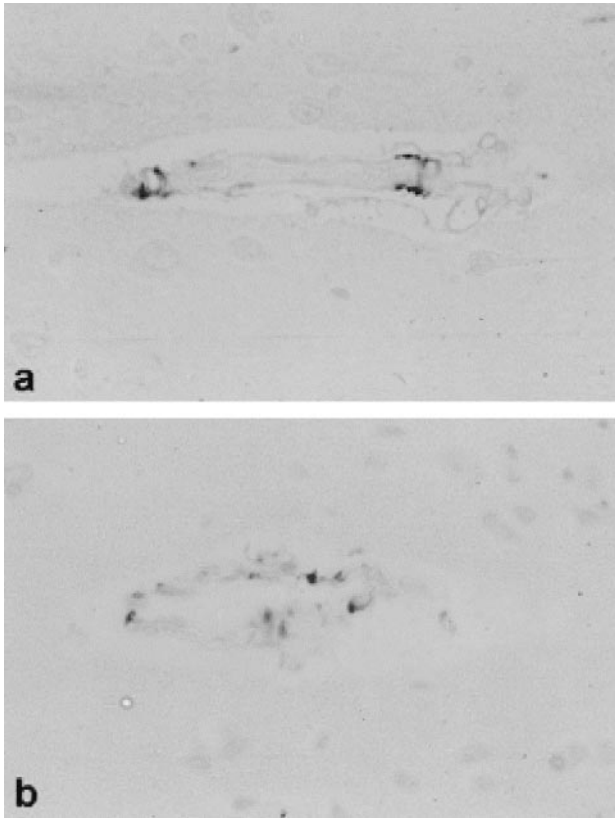


Figure 3. HNE immunohistochemistry in control (a) and HBO-treated (b) rats (original magnification $\times 640$) shows some labeled endothelial cells. Importantly, there is no difference between experimental groups.

ment periods between 40 minutes and 3 hours at 2 to 3 atm in a time window of <4 to 6 hours after various insults.^{1,2,6,8,17,18} With this paradigm, the final infarct size could be reduced by 38%, almost similar to a previously demonstrated reduction after permanent ligation of the MCA.²

In vivo MR monitoring of ischemia could be important to study onset, duration, and effectiveness of any treatment paradigm. In the present study, MRI showed that initiation of HBO treatment reversed lesion size between 3 and 5 hours after ischemia and remained effective during the whole experiment. Such a treatment pattern was shown to occur with classic neuroprotectants, eg, NMDA antagonists, and is different from the delayed effects of growth factors in which protection began as late as 24 hours after stroke.^{13,19}

One problem with HBO treatment for stroke is the potential oxidative stress in particular after transient ischemia.^{20,21} In this study, lipid membrane peroxidation was detected by an antibody against HNE-modified proteins,^{22,23} which almost exclusively originate from phospholipid-bound arachidonic acid and may be the most reliable index of free-radical-induced lipid peroxidation.¹⁵ Whereas HNE was demonstrated to increase after several pathological conditions of oxidative stress, such as ischemia liver diseases or copper- and iron-induced oxidative damage,²³ no such increase was detectable in our present permanent ischemia study, which correlates to previous studies.² Only 1 other aldehyde, malondialdehyde, was demonstrated to have significant biologi-

cal significance as an indicator for lipid peroxidation. Malondialdehyde was transiently increased in healthy rats treated with HBO or after reperfusion without HBO.^{24,25} Our present findings, however, clearly demonstrate that HBO treatment does not lead to increased lipid peroxidation compared with room air-treated controls. In addition, the transcription factor c-FOS, known as a sensitive indicator of stress in general²⁶ and as marker for oxidative stress,²⁷ was quite equally induced in the ischemic hemisphere in both experimental groups.

Mechanism of neuroprotection of HBO treatment after ischemia is thought to be mediated by improved oxygen supply to the ischemic periphery. Arterial oxygen pressure and content were increased after HBO treatment, indicating a 20% improvement of oxygen supply to the ischemic periphery.² Oxygen delivery to the ischemic penumbra may improve energy failure of compromised tissue and reduce the susceptibility to spreading depressions, causing further deterioration of energy status of tissue at risk.²⁸ A microdialysis study demonstrated reduced levels of glutamate and lactate in the ischemic core, suggesting reduced excitotoxicity as biological basis of HBO treatment.⁶ Other potential protective mechanisms include increase of expression of protective genes of radical scavengers, inhibition of mediators of leukocyte adhesion, and reperfusion injury such as neutrophil beta-2-integrin or the proinflammatory cyclooxygenase-2.^{29–31} HBO treatment, furthermore, reduced brain vascular permeability, as measured with Evans blue extravasation after global cerebral ischemia.³² However, in the same study, HBO treatment exhibited adverse effects on CBF and reduced CBF 90 minutes after oxygenation. Elevations of PaO₂ are associated with cerebral vasoconstriction and could account for reduction of CBF during HBO.³³ This phenomenon is regarded as a transient effect that disappears after exposure when CBF returns to normal.^{2,34} These findings are consistent with our results in the present study in which CBF was unchanged after HBO treatment as measured by PWI.

In conclusion, our data clearly indicate that HBO treatment in a relevant clinical situation, namely 2 hours after stroke onset, is neuroprotective. As monitored by MRI, HBO treatment can reverse lesion size in the critical phase between 3 and 5 hours after stroke and remains effective up to 5 days, resulting in improved neurological outcome. Importantly, markers for oxidative stress are not increased. Future projects focusing on the potential neuroprotective effect of normobaric hyperoxia alone, which may also ameliorate ischemic damage, are needed.³⁵ With respect to the clinical situation, that would be an exciting perspective.

Acknowledgments

This work contains parts of the thesis of Holger Schade. We greatly appreciate the technical assistance of Stephan Hennes and Frank Malischewsky.

References

- Burt JT, Kapp JP, Smith RR. Hyperbaric oxygen and cerebral infarction in the gerbil. *Surg Neurol.* 1987;28:265–268.
- Sunami K, Takeda Y, Hashimoto M, Hirakawa M. Hyperbaric oxygen reduces infarct volume in rats by increasing oxygen supply to the ischemic periphery. *Crit Care Med.* 2000;28:2831–2836.

3. Kawamura S, Yasui N, Shirasawa H, Fukasawa H. Therapeutic effects of hyperbaric oxygenation on acute focal cerebral ischemia in rats. *Surg Neurol.* 1990;34:101–106.
4. Veltkamp R, Warner DS, Domoki F, Brinkhous AD, Toole JF, Busija DW. Hyperbaric oxygen decreases infarct size and behavioral deficit after transient focal cerebral ischemia in rats. *Brain Res.* 2000;853:68–73.
5. Yang ZJ, Camporesi C, Yang X, Wang J, Bosco G, Lok J, Gorji R, Schelper RL, Camporesi EM. Hyperbaric oxygenation mitigates focal cerebral injury and reduces striatal dopamine release in rat model of middle cerebral artery occlusion. *Eur J Appl Physiol.* 2002;87:101–107.
6. Badr AE, Yin W, Mychaskiw G, Zhang JH. Effect of hyperbaric oxygen on striatal metabolites: a microdialysis study in awake freely moving rats after MCA occlusion. *Brain Res.* 2001;916:85–90.
7. Rysniak DE, Kirk MA, May JD, Kao LW, Brizendine MS, Welch JL, Cordell WH, Alonso RJ. Hyperbaric oxygen therapy in acute ischemic stroke: results of the hyperbaric oxygen in acute ischemic stroke trial pilot study. *Stroke.* 2003;34:571–574.
8. Weinstein PR, Anderson GG, Telles DA. Results of hyperbaric oxygen therapy during temporary middle cerebral artery occlusion in unanesthetized cats. *Neurosurgery.* 1987;20:518–524.
9. Longa EZ, Weinstein PR, Carlson S, Cummins R. Reversible middle cerebral artery occlusion. *Stroke.* 1989;20:84–91.
10. Heiland S, Reith W, Forsting M, Sartor K. Perfusion-weighted magnetic resonance imaging using a new gadolinium complex as contrast agent in a rat model of focal cerebral ischemia. *J Magn Reson Imaging.* 1997;7:1109–1115.
11. Perez-Trepichio AD, Xue M, Ng TC, Majors AW, Furlan AJ, Awad IA, Jones SC. Sensitivity of magnetic resonance diffusion-weighted imaging and regional relationship between the apparent diffusion coefficient and cerebral blood flow in rat focal cerebral ischemia. *Stroke.* 1995;26:667–675.
12. Menzies SA, Hoff JT, Betz L. Middle cerebral artery occlusion in rats: a neurological and pathological evaluation of a reproducible model. *Neurosurgery.* 1992;31:100–107.
13. Schäbitz WR, Hoffmann TT, Heiland S, Kollmar R, Bardutzky J, Sommer C, Schwab S. Delayed neuroprotective effect of IGF-I after experimental transient focal cerebral ischemia monitored with MRI. *Stroke.* 2001;32:1226–1233.
14. Tanaka T, Nishiyama Y, Okada K, Hirota K, Matsui M, Yodoi J, Hiai H, Toyokuni S. Induction and nuclear translocation of thioredoxin by oxidative damage in the mouse kidney: independence of tubular necrosis and sulfhydryl depletion. *Lab Invest.* 1997;77:145–155.
15. Esterbauer H, Schaur RJ, Zollner H. Chemistry and biochemistry of 4-hydroxynonenal, malondialdehyde and related aldehydes. *Free Radic Biol Med.* 1991;11,81–128.
16. Engelhorn T, von Kummer R, Reith W, Forsting M, Doerfler A. What is effective in malignant middle cerebral artery infarction: reperfusion, craniectomy, or both? An experimental study in rats. *Stroke.* 2002;33:617–622.
17. Corkill G, Van Housen K, Hein L, Reitan J. Videodensitometric estimation of the protective effect of hyperbaric oxygen in the ischemic gerbil brain. *Surg Neurol.* 1985;24:206–210.
18. Chang CF, Niu KC, Hoffer BJ, Wang Y, Borlongan CV. HBO therapy for treatment of postischemic stroke in adult rats. *Exp Neurol.* 2000;66:298–306.
19. Tatlisumak T, Takano K, Carano RA, Fisher M. Effect of bFGF on experimental focal ischemia studied by diffusion-weighted and perfusion imaging. *Stroke.* 1996;27:2292–2297.
20. Bromont C, Marie C, Bralet J. Increased lipid peroxidation in vulnerable brain regions after transient forebrain ischemia in rats. *Stroke.* 1989;20:918–924.
21. Sakamoto A, Ohnishi ST, Ohnishi T, Ogawa R. Relationship between free radical production and lipid peroxidation during ischemia-reperfusion injury in the rat brain. *Brain Res.* 1991;554:186–192.
22. Toyokuni S, Uchida K, Okamoto K, Hattori-Nakakuki Y, Hiai H, Stadtman ER. Formation of 4-hydroxy-2-nonenal-modified proteins in the renal proximal tubules of rats treated with a renal carcinogen, ferric nitrilotriacetate. *Proc Natl Acad Sci U S A.* 1994;91:2616–2620.
23. Toyokuni S. Reactive oxygen species-induced molecular damage and its application in pathology. *Pathol Int.* 1999;49:91–102.
24. Noda Y, McGeer PL, McGeer EG. Lipid peroxide distribution in brain and the effect of hyperbaric oxygen. *J Neurochem.* 1983;40:1329–1332.
25. Yoshida S, Inoh S, Asano T, Sano K, Kubota M, Shimazaki H, Ueta N. Effect of transient ischemia on free fatty acids and phospholipids in the gerbil brain. Lipid peroxidation as a possible cause of postischemic injury. *J Neurosurg.* 1980;53:323–331.
26. Kovacs KJ. c-Fos as a transcription factor: a stressful (re)view from a functional map. *Neurochem Int.* 1998;33:287–297.
27. Vollgraf U, Wegner M, Richter-Landsberg D. Activation of AP-1 and nuclear factor-kappaB transcription factors is involved in hydrogen peroxide-induced apoptotic cell death of oligodendrocytes. *J Neurochem.* 1999;73:2501–2509.
28. Hossmann KA. Viability thresholds and the penumbra of focal ischemia. *Ann Neurol.* 1994;36:557–565.
29. Thom SR. Functional inhibition of leukocyte B2 integrins by hyperbaric oxygen in carbon monoxide-mediated brain injury in rats. *Toxicol Appl Pharmacol.* 1993;123:248–256.
30. Thom SR, Mendiguren I, Hardy K, Bolotin T, Fisher D, Nebolon M, Kilpatrick L. Inhibition of human neutrophil B2-integrin-dependent adherence by hyperbaric oxygen. *Am J Physiol.* 1997;272:C770–C777.
31. Yin W, Badr AE, Mychaskiw G, Zhang JH. Down regulation of Cox-2 is involved in hyperbaric oxygen treatment in a rat transient focal ischemia model. *Brain Res.* 2002;926:165–171.
32. Mink RB, Dutka AJ. Hyperbaric oxygen after global cerebral ischemia in rabbits does not promote brain lipid peroxidation. *Crit Care Med.* 1995;23:1398–1404.
33. Miller JD, Ledingham IM, Jennett WB. Effects of hyperbaric oxygen on intracranial pressure and cerebral blood flow in experimental cerebral oedema. *J Neurol Neurosurg Psychiatry.* 1970;33:745–755.
34. Regli F, Yamaguchi T, Waltz AG. Effects of inhalation of oxygen on blood flow and microvasculature of ischemic and nonischemic cerebral cortex. *Stroke.* 1970;1:314–319.
35. Singhal AB, Dijkhuizen RM, Rosen BR, Lo EH. Normobaric hyperoxia reduces MRI diffusion abnormalities and infarct size in experimental stroke. *Neurology.* 2002;58:945–952.